



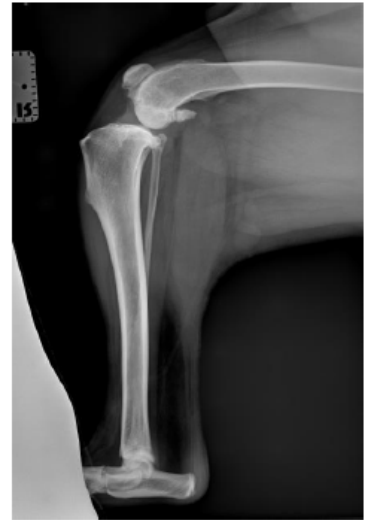
Lone Star Veterinary Surgical Specialists

Surgical Solutions for Your Loved Pets

Positioning for TPLO images

Lateral:

- Patient is placed in lateral, with hip, stifle, tarsus all resting flat on the plate/table top
- Pull unaffected leg away (cranially), position stifle/tarsus at 90° angles
- Collimate beam to center crosshairs on stifle, making sure to get hock in view
- Femoral condyles should overlap



Cranial-Caudal:

- The patient is positioned in dorsal/sternal recumbency.
- Pull the affected limb distal and straight so that patella is directly above the table. Do not twist or rotate the tarsal joint or paw.
- Center the crosshairs on the stifle again. Include the stifle, entire tibia and tarsus in the exposure. In the radiograph the patella should be centered between both fabella. The medial border of the calcaneus should be aligned with the center of the tibiotarsal joint.

